

DIFFERENCE IN CYCLOOXYGENASE-2 (COX-2) EXPRESSION BETWEEN LOW AND HIGH GRADE PAPILLARY CARCINOMA IN HUMAN BLADDER CANCER

Yulizar, DR¹, Hardjowijoto, S², Djatisoesanto, W²; Soemarno, T³

¹Department of Urology, Ulin Hospital, Banjarmasin, South Kalimantan

²Department of Urology, Airlangga University School of Medicine, Dr Soetomo Teaching Hospital Surabaya

³Department of Anatomic Pathology, Airlangga University School of Medicine, Dr Soetomo Teaching Hospital Surabaya

ABSTRACT

The objective of this study was to improve the estimation of the prognostic behavior by difference of cyclooxygenase-2 (COX-2) expression between low and high grade papillary carcinoma of human transitional cell bladder cancer. We used COX-2 expression as a parameter for prognostic behavior. It was studied by immunohistochemical methods in 36 samples of human transitional cell carcinoma of the bladder from pathology archive. COX-2 immunostaining identifies intracytoplasmic content of COX-2 in human bladder cancer cell, measured by scale of staining which is scored 0 (0-9.9%), 1 (10-49.9%), 2 (50-99.9%) and scale of immunostaining intensity which was scored 0 (negative), 1+ (weak), 2+ (strong). The results of this study revealed that COX-2 immunostaining identified 19 high grade papillary carcinoma (16 samples were 2+(strong), 2 samples were 1+(weak), and 1 sample was 0 (negative) and 17 low grade papillary carcinoma (9 samples were 2+(strong), 3 samples were 1+(weak), and 5 samples were 0 (negative). There was a distribution difference in COX-2 expression between low grade and high grade papillary carcinoma ($p = 0.035$) analyzed by the Mann-Whitney test, favoring more strong of COX-2 expression in high grade tumor than expected with equal distribution. In conclusions, these findings suggest that the difference in COX-2 expression in may be used as an additional biomarker of its progressiveness.

Keywords: cyclooxygenase-2, high grade papillary carcinoma, low grade papillary carcinoma, bladder cancer, transitional cell carcinoma

Correspondence: Yulizar D, Department of Urology, Ulin Hospital, Jalan Jend. A Yani Km 2 no. 43, Banjarmasin, South Kalimantan, phone 62-511-3264965, email: deddyry@yahoo.com

INTRODUCTION

Most of mortality cases in bladder malignancy belong to invasive Transitional Cell Carcinoma (TCC) type, in which the metastasis has been resistant against chemotherapy. Superficial bladder malignancy is commonly present as low grade TCC and it endoscopically can be easily resected, but its recurrence rate is high and its incidence is higher than those of invasive types (Kiemeny et al. 1993). Therefore, a safer and more effective immunotherapeutic or instillation chemotherapeutic agent has been developed. In an epidemiological study it was found that cyclooxygenase (COX) involved in the pathogenesis of malignancy and the increase of cyclooxygenase-2 (COX-2) enzyme in various malignancies, such as colon, pulmonary, abdominal, and esophageal tumor, confirms the involvement of COX-2 in carcinogenesis (Koki 2002). The effect of COX-2 increasing results in advanced cell division, the inhibition of tumor cell apoptosis, the change of cell adhesion, the increase of tumor cell motility, the

induction of neovascularization, immunosurveillance reduction, and angiogenesis improvement (Koki 2002; Moore 2003). The role of COX-2 in colorectal, pulmonary, and abdominal malignancies has been widely studied, while its role in bladder malignancies remains rare (Koki 2002). Therefore, this study was performed to find the increase of COX-2 expression in bladder TCC and the difference of COX-2 expression between low and high grade papillary carcinoma in bladder TCC.

MATERIALS AND METHODS

This was an analytic observational study using cross-sectional design investigating the expression of COX-2 in bladder TCC and the difference of COX-2 expression between low and high grade papillary carcinoma in bladder transitional cells. This study was performed from August to October 2006 and 36 samples that met the inclusion criteria were randomly obtained. HE staining was conducted to determine the histopathological grading

of bladder TCC and immunohistochemical test using NCL-COX-2 mouse monoclonal antibody to determine COX-2 expression. The grade of COX-2 expression was the expression of COX-2 occurred in bladder transitional cell carcinoma, in which the estimation was based on the percentage of tumor whose nucleus were positively stained using antibody against COX-2 (NCL-COX-2). COX-2 expression was shown in positive tumor percentage scale and estimated semiquantitatively in scores 0 (0%-9.9%), 1 (10%-49.9%), and 2 (50%-99.9%). Immunostaining intensity was based on the values of 0 (negative), 1+ (weak), 2+ (strong). The grade of transitional cell carcinoma was determined based on WHO and ISUP criteria, i.e., papillary neoplasm of low malignant potential (Grade 1), low-grade papillary carcinoma (Grade 2), and high-grade papillary carcinoma (Grade 3).

RESULTS

We obtained 1 sample of papillary neoplasm preparation of low malignant potential, 17 samples of low grade papillary carcinoma, and 19 samples of high grade papillary carcinoma of bladder TCC. The degree of COX-2 expression is varied in each gradation. From 17 samples of low grade papillary carcinoma there were respectively 5 samples with negative COX-2 expression, 3 samples weakly positive, and 9 samples strongly positive. From 19 samples of high grade papillary carcinoma, there were 1 sample with negative COX-2 expression, 2 samples weakly positive, and 16 samples strongly positive. From collected samples that consisted of 37 preparations, the range of the patients' age was 33 to 77 years, with mean 58.36 years, and median 60 years. From those collected samples, 31 preparations (84%) were from male bladder TCC patients, and 6 (16%) from female patients.

Table 1. Bladder TCC grading according to age group

Bladder TCC grading	Age group (year)			Total
	< 50	50 – 60	> 60	
Papillary Neoplasm of Low Malignant Potential	0	0	1	1
Low grade papillary carcinoma	6	5	6	17
High grade papillary carcinoma	2	8	9	19
Total	8	13	16	37

Table 1 shows that from 37 studies samples, there were 16 samples from patients of more than 60 years old. From

these, 1 sample was papillary neoplasm of low malignant potential, 6 samples low grade papillary carcinoma, and 9 samples high grade papillary carcinoma of bladder TCC. Thirteen samples were from age group 50 - 60 years, comprising 5 samples with low grade papillary carcinoma and 8 samples with high grade papillary carcinoma of bladder TCC. In age group of less than 50 years, there were 8 samples, comprising 6 with low grade papillary carcinoma and 2 samples with high grade papillary carcinoma of bladder TCC.

Table 2. COX-2 expression according to age group

COX-2 expression	Age groups (year)			Total
	< 50	50 – 60	> 60	
Negative	1	1	4	6
Weak expression	2	2	2	6
Strong expression	5	10	10	25
Total	8	13	16	37

Table 2 shows that COX-2 expression was negative in 6 samples, comprising 1 sample in age group of less than 50 years and age group of 50-60 years, and 4 samples in age group more than 60 years. Weak COX-2 expression was found in 6 samples, comprising 2 samples in each age group. However, a strong COX-2 expression was found in 25 samples, comprising 5 samples of age group less than 50 years, 10 samples of 50-60 years, and 10 samples of more than 60 years.

Table 3. Bladder TCC grading according to sex

Bladder TCC grading	Sex		Total
	Male	Female	
Papillary Neoplasm of Low Malignant Potential	1	0	1
Low grade papillary carcinoma	15	2	17
High grade papillary carcinoma	15	4	19
Total	31	6	37

Table 3 shows that there were 31 male samples, comprising 1 sample with papillary neoplasm of low malignant potential, and each 15 samples in each low grade group and high grade papillary carcinoma of bladder TCC. There were 6 female samples, comprising 2 samples with low grade papillary carcinoma and 4 samples with high grade papillary carcinoma of bladder TCC.

Table 4. Distribution of bladder TCC grading to COX-2 expression

Bladder TCC grading	COX-2 expression			Total
	Negative	Weak	Strong	
Papillary Neoplasm of Low Malignant Potential	0	1	0	1
Low grade papillary carcinoma	5	3	9	17
High grade papillary carcinoma	1	2	16	19
Total	6	6	25	37

Table 4 proves that in high grade papillary carcinoma the strong, weak, and negative COX-2 expression were found in respectively 16, 2, and 1 samples, while in low grade papillary carcinoma the COX-2 expression was respectively 9, 3, and 5 samples. The result of data normality test can be seen in Table 5.

Table 5. Data normality test of the distribution of bladder TCC grading and COX-2 expression

Variables	1-Sample Kolmogorov-Smirnov test	
	Z test	p
Bladder TCC Grading	2.114	0.0001
COX-2 expression	2.541	0.0001

The result of data distribution normality test in Table 5 indicates that the variables of bladder TCC grading variable and COX-2 expression have no normal distribution ($p = 0.0001$). Therefore, subsequent analysis using non-parametric test was performed. The non-parametric test was Mann-Whitney comparative test using SPSS application version 12. The result of Mann-Whitney comparative test in this study is presented in Table 6.

Table 6. Comparative test of COX-2 expression between Low dan High Grade Papillary Carcinoma of Bladder TCC

COX-2 Expression	N	Mean Rank	Z test	p
Low grade papillary carcinoma	17	15.32	-2.109	0.035
High grade papillary carcinoma	19	21.34		
Total	36			

Based on the result of statistical test on Table 6, it was found that COX-2 expression in low grade papillary carcinoma preparation was significantly different from high grade papillary carcinoma preparation of bladder

TCC ($p = 0.035$). From Table 6, it can be inferred that high grade papillary carcinoma has averagely stronger expression as compared to low grade papillary carcinoma of bladder TCC.

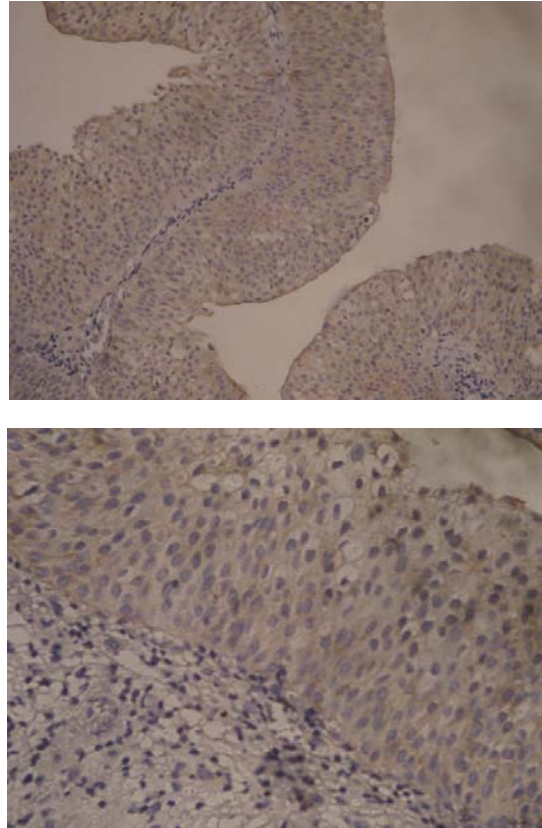


Figure 1. Weak COX-2 expression in low grade papillary carcinoma in bladder TCC, magnification 40x and 100x.

Immunohistochemical staining examination to observe COX-2 expression is conducted prior to bladder TCC histopathological examination using HE staining with light microscope. COX-2 expression can be observed in the cytoplasm of the cell by counting the count of the cells that exhibiting brown color and the intensity was based on the degree of strength of the resulted brown in comparison with ulcerative colitis preparations, which is in line with the protocol recommended in NCL-COX2 (Novocastra Laboratory Ltd.)

In this study, we also found only one preparation that showed papillary neoplasm of low malignant potential from bladder TCC with negative COX-2 expression, while preparations showing low grade papillary carcinoma comprised 17 slides with COX-2 expression varied from

negative in 5 preparations, weakly positive 3 preparations, and strongly positive 9 preparations. Preparations with high grade papillary carcinoma consisted of 19 slides with varied COX-2 expression from negative in 1 preparation, weakly positive in 2 preparations, and strongly positive in 16 preparations.

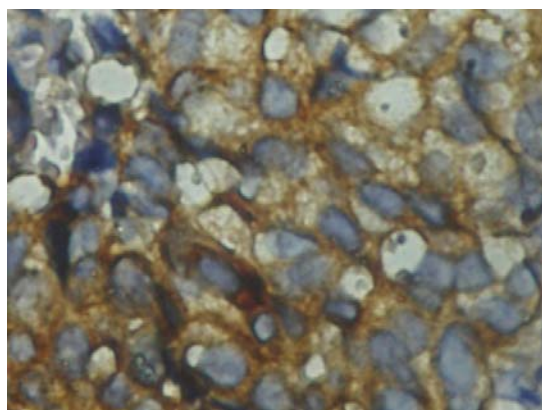


Figure 2. Strong COX-2 expression in high grade papillary carcinoma in bladder TCC, magnification 40x and 100x.

The result of statistical analysis conducted to find the difference of COX-2 expression between low grade and high grade papillary carcinoma using Mann-Whitney comparative test revealed $p = 0.035$, indicating that there was significant difference in COX-2 expression from both gradations, the low grade and high grade papillary carcinoma of bladder TCC. The result of another study found significant correlation between pathological clinical parameter and COX-2 expression. COX-2 immunoreactivity is significantly correlated with grade III ($p < 0.002$) or high-grade ($p < 0.0003$) of bladder urothelial carcinoma (Komhoff et al. 2000). The increase of COX-2 expression in high grade papillary carcinoma of

bladder TCC in this study, as in other previous studies (Komhoff et al. 2000; Mohammed et al. 1999) possibly involved the increase of COX-2 at the initial event of high grade bladder tumorigenesis process, either biologically or cytologically. In contrast, the weakness of COX-2 expression in high grade tumor cells, as well as the reduction of expression in low grade carcinoma, demonstrated the involvement of COX-2 in tumor progressiveness regulation from low to high grade. In several other studies, there was correlation between increased COX-2 expression and the poor prognosis of the malignant disease (Kyzas 2005).

Table 7. COX-2 expression in low and high grade papillary carcinoma of bladder TCC

Bladder TCC Grade	COX-2 expression			Total
	Negative	Weak	Strong	
High grade papillary carcinoma	1	2	16	19
Low grade papillary carcinoma	5	3	9	17
Total	6	5	25	36

CONCLUSION

In conclusion, the expression of cyclooxygenation (COX-2) in high grade papillary carcinoma is averagely stronger than its expression in low grade papillary carcinoma of bladder transitional cell carcinoma (TCC).

ACKNOWLEDGMENT

The authors thank to Widodo J. Pudjirahardjo, dr, MPH, MS, Dr.PH. for his meaningful contribution in statistical analysis in this study.

REFERENCES

- Aschorijanto, A & Soetojo 2004, *Gambaran Penderita Karsinoma Buli di RSUD Dr. Soetomo Surabaya antara Tahun 2001-2003. Penelitian Retrospektif*, Department of Urology, Airlangga University School of Medicine, Dr. Soetomo Teaching Hospital, Surabaya
- Bartoletti, R, Cai, T, Nesi, G, Sardi, I, Rizzo, M 2005, 'Qualitative and quantitative analysis of angiogenic factors in transitional cell bladder carcinoma: Relationship with clinical course at 10 years follow-up', *Oncology Reports*, vol. 14, pp. 251-255.
- Dohadwala, M, Luo, J, Zhu, L, et al. 2001, 'Non-small cell lung cancer cyclooxygenase-2-dependent invasion is

- mediated by CD44', *J Bio Chem*, vol. 276, pp. 20809-20812.
- Feldman, AR, Kessler, L, Myers, MH, Naughton, MD 1986, 'The prevalence of cancer: estimates based on the Connecticut Tumor Registry', *N Engl J Med*, vol. 3115, pp. 1394-1397.
- Komhoff, M, Guan, Y, Shappell, HW, Davis, L, Jack, G, Shyr, Y, Koch, MO, Shappel, SB, Breyer, MD 2000, 'Enhanced expression of cyclooxygenase-2 in high grade human transitional cell bladder carcinoma', *Am J Pathol*, vol. 157, pp. 29-35.
- Kyzas, PA, Stefanou, D, Agnantis, NJ 2005, 'COX-2 expression correlates with VEGF-C and lymph node metastases in patients with head and neck squamous cell carcinoma', *Modern Pathology*, vol. 18, pp. 153-160.
- Mohammed, SI, Knapp, DW, Bostwick, DG, Foster, RS, Khan, KNM, Masferrer, JL, Woerner, BM, Snyder, PW, Koki, AT 1999, 'Expression of cyclooxygenase-2 (COX-2) in human invasive transitional cell carcinoma (TCC) of the urinary bladder', *Cancer Res*, vol. 59, pp. 5647-5650.
- Mokos, I, Jakic-Razumovic, J, Marekovic, Z, Pasini, J 2006, 'Association of cyclooxygenase-2 immuno reactivity with tumor recurrence and disease progression in superficial urothelial bladder cancer', *Tumori*, vol. 92, pp. 124-129.
- Moore, BC & Simmons, DL 2003, *COX-2 Inhibition, Apoptosis, and Chemoprevention by Nonsteroidal Anti-inflammatory Drugs*, Retrieved Feb 14, 2003, from <http://www.bentham.org/cmc-sample/simmons/simmons.htm>
- Steinberg, GD, Kim, HL, Sachdeva, K, Curti, B 2004, *Bladder Cancer*, retrieved from <http://www.eMedicine.com>.
- Wu, R 2005, 'Urothelial tumorigenesis: A tale of divergent pathways', *Nat Rev Cancer*, vol. 5, no. 9, pp. 713-725.